

# Surgical Enucleation of an Uncommon Complex Odontoma: A Case Report

About the Author(s)

Naveen Farooq<sup>1\*</sup>, Fouzia Aslam<sup>2</sup>

<sup>1</sup>Assistant professor, Department of Community Dentistry, HBS Dental College, Islamabad

<sup>2</sup>Assistant professor, Department of Oral and maxillofacial surgery, HBS Dental Hospital, Islamabad

Correspondence: naveen@hbs.edu.pk  
HBS Medical and Dental College, Islamabad

Received: May 01, 2023

Revised: September 13, 2023

Accepted: October 24, 2023

Published: January 05, 2024

DOI: <https://doi.org/10.70394/jhbsmdc.v3i2.39>

## Abstract

Odontomes are developmental malformations that are produced by the growth of completely differentiated mesenchymal as well as epithelial cells responsible for the formation of odontoblasts and ameloblasts. There are two types of odontomas i.e., Complex and compound. In complex odontome, all dental tissues are present, but are disorderly organised, dissimilar to teeth. On X-ray, complex odontoma appears as a distinct radio-opacity, occasionally encircled by a thin radiolucent region. This case report presents an uncommon type of complex odontoma where patient reported with pain along with the large swelling in the posterior mandibular region without eruption. Enucleation was the treatment of choice.

**Keywords:** Odontoma, complex odontoma, mesenchymal and epithelial cells, radio-opacity, Enucleation.

**Conflict of Interest:** None

**Funding Source:** None

## Introduction

Odontomes also called as odontomas are developmental anomalies that are formed by the development of completely differentiated mesenchymal as well as epithelial cells that produce odontoblasts and ameloblasts. These are benign tumors made up of dentin and enamel but may also contain cementum and pulp<sup>1</sup>. The word odontoma (or odontome) was labelled firstly by Paul Broca, in 1867<sup>2</sup>. According to WHO (World Health Organisation), there are two types of odontomes. A deformity in which all dental tissues are present, but disorderly organised is called Complex Odontoma. While an anomaly having all of the dental tissues arranged in a more orderly manner as compared to complex odontoma is known as Compound odontoma<sup>3,4</sup>. In 2005, WHO characterised complex odontomes as irregular solidified mass that are not similar to teeth whereas compound odontomes are calcified mass that have similarity to the tooth structure<sup>5</sup>. The most common location of complex Odontoma is posterior mandibular jaw.

While compound odontomas are mostly present in the anterior region of maxilla<sup>6</sup>. Changes in the genetic make accountable for dental growth, trauma to deciduous teeth and hyperactivity of odontoblasts are included in the

aetiology of odontomas<sup>7</sup>. Conventional surgical removal of the lesion is treatment of choice<sup>8</sup>.

This case report presents an uncommon case of complex odontoma in a 17-year-old female. Informed consent was taken for publication of this report and any associated pictures

## Case report

A 17 years old female, reported to Oral and maxillofacial surgery department of a teaching hospital presented with history of mild dull pain and swelling in right lower mandibular region for 06 months. Extraoral examination showed an isolated swelling measuring 3 × 2 cm, present on the right side of mandible ranging from body of the mandible to the ramus. On palpation, the swelling was firm, hard, nonreducible and resistant to compression [Figure 1].

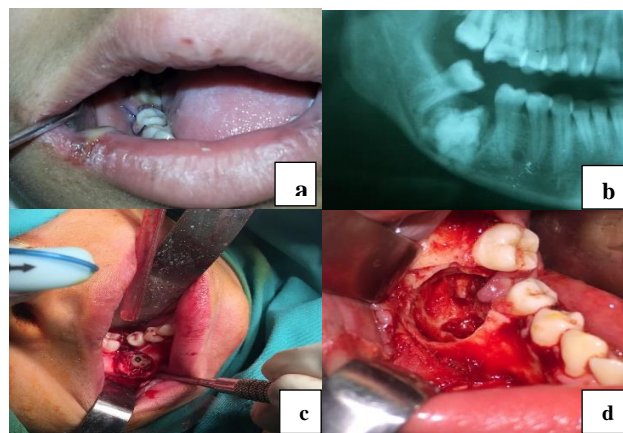
Intraoral examination revealed missing 46 and mesially tilted 47. There was expansion of buccal cortical plate in the region of mandibular right first molar. An OPG (Orthopantomogram) was done. OPG displayed a radiopaque mass surrounded by a thin radiolucent lining extending from mandibular right first premolar to right 2nd molar. The upper part of the mass was bulging towards the superior border of the mandible.

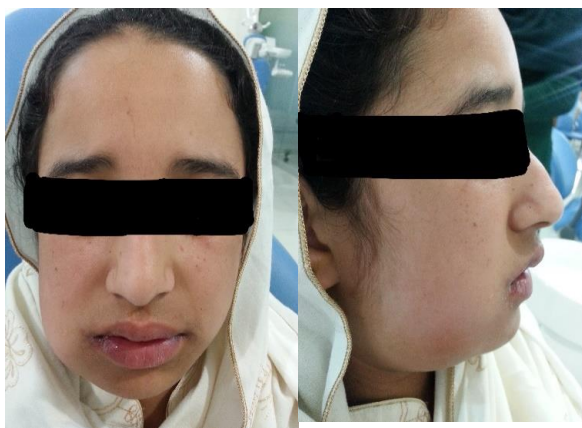

Figure 1: Frontal and Lateral view of swelling in the right lower region of the face

The provisional diagnosis of this case was complex odontoma. Surgical removal of the odontome under GA (General anaesthesia) was planned.

Routine blood tests were done. The lesion was approached intraorally and it was completely excised. The area was curettage deeply. 3-0 vicryl suture was used to close the wound. The sample was sent to laboratory for histopathological assessment. Diagnosis of complex odontome was confirmed after the lab result [Figure 2].



**Figure 2:** **a:** Intraoral examination showing missing # 46. **b:** OPG revealed a radio-opacity surrounded by a radiolucent lining **c:** The lesion was operated intraorally. **d:** The lesion was completely enucleated under GA.

The patient was observed for 7-months. Postoperative orthopantomogram showed good healing without any bony defect. There was no sign of relapse. After surgery, there was no numbness or tickling sensation on the right side of the mandible.

## Discussion

The complex odontoma shows disorderly organization of dental tissues even though complete differentiation of the

cells of the enamel organ has done. The odontoma is mostly covered by the connective tissue. An X-ray is the most accurate technique to distinguish between complex and compound odontomes as compared to clinical and manual examination<sup>9</sup>. Generally, odontomas are small and asymptomatic; but sometimes they may grow large, resulting in bone expansion. When odontomas erupt, swelling, pain and infection are most common symptoms, which happen very rare<sup>10,11</sup>. In the present case, the patient reported with pain and swelling in the lower posterior region without eruption.

On X-ray, odontomas appear as a well-demarcated radio-opaque mass along with a radiolucent cavity surrounded by a thin sclerosed lining. Radiolucent region is the connective tissue covering of a normal dental follicle<sup>12</sup>. In the present case, complex odontoma appears as a distinct radio-opacity, encircled by a thin radiolucent region on X-ray.

Surgical removal is the best possible treatment for odontomas. The purpose is to eradicate the mechanical obstruction and then probable eruption of secondary teeth. Complete removal of the lesion decreases the chance of relapse<sup>13</sup>. The lesion was also completely enucleated in this present report and did not show any recurrence during the seven months of follow up. Bone grafts are used to fill any bony defect, if found after the surgical removal of odontomes<sup>13</sup>. The present case report showed good intraoral healing without any bony fault.

Pralidoxime (2-PAM) also should be given to affect the nicotinic receptors since atropine only works on muscarinic receptors. Pralidoxime works by reactivating the phosphorylated AChE by binding to the organophosphate. However, to work, it has to be given within 48 hours of the poisoning. The agent does not depress the respiratory center and can be combined with atropine. Atropine must be given before 2-PAM to avoid worsening of muscarinic-mediated symptoms. A bolus of at least 30 mg/kg in adults or 20 to 50 mg/kg for children should be given over 30 minutes. Rapid administration can cause cardiac arrest. After the bolus, a continuous infusion of at least 8 mg/kg/hr for adults and 10 to 20 mg/kg/hr for children should be started and may be needed for several days.<sup>6-7</sup> Patients with seizures may benefit from benzodiazepines.

## Conclusion

This was a case of complex odontoma occurred rarely as compared to compound odontomas. This complex odontoma presented with pain along with the large swelling in the posterior mandibular region. Surgical enucleation was the treatment option. Postoperative

orthopantomogram showed good healing of bone without any defect and recurrence. To improve the diagnosis, treatment and prognosis, it is very important to have the adequate information and knowledge of all the jaw tumors.

## References

1. Neville B, Damm D, Allen C, Chi A. Oral and maxillofacial pathology [Internet]. 2015 [cited 2022 Sep 1].
2. Tiwari A, Srinivas K, Ratnakar P, Jyoti G, Saluja SA. Complex odontome—a rare case report. *Am J Oral Med Rad.* 2016;3:119-21.
3. Philipsen H, Reichart P, oncology FP-O, 1997. Mixed odontogenic tumours and odontomas. Considerations on interrelationship. Review of the literature and presentation of 134 new cases of odontomas. Elsevier [Internet]. [cited 2022 Sep 1].
4. Holzinger R, Acton W, ... WB-A, 2019. Validity and limitations of simple reaction kinetics to calculate concentrations of organic compounds from ion counts in PTR-MS. *amt.copernicus.org* [Internet]. [cited 2022 Sep 1].
5. Kumar BP, Nikhila K, Srinivas G, Devi VV. Complex Odontoma—A Case Report. *Indian J Dent Adv* [Internet]. 2019 Jul 1 [cited 2022 Sep 5];11(3):112–7.
6. Sciences JM-JD and M, 2020. Odontoma: Case Report. *academia.edu* [Internet]. [cited 2022 Sep 5].
7. Salgado H, Estomatologia PM- de, Cirurgia MD e, 2013. Compound odontoma—case report. Elsevier [Internet]. [cited 2022 Sep 5].
8. Reddy GSP, Reddy G V., Sidhartha B, Sriharsha K, Koshy J, Sultana R. Large Complex Odontoma of Mandible in a Young Boy: A Rare and Unusual Case Report. *Case Rep Dent.* 2014;2014:1–4.
9. Stafne EC. Value of roentgenograms in diagnosis of tumors of the jaws. *Oral Surg Oral Med Oral Pathol* 1953;6:82-92. - Google Search [Internet]. [cited 2022 Sep 5].
10. Bhaskar SN. Synopsis of oral pathology. *Acad Med...* - Google Scholar [Internet]. [cited 2022 Sep 5].
11. Vengal M, Arora H, ... SG-J of the C, 2007. Large erupting complex odontoma: a case report. *researchgate.net* [Internet]. 2007 [cited 2022 Sep 8]
12. Chrcanovic B, Jaeger F, Freire-Maia B. Two-stage surgical removal of large complex odontoma. *Oral Maxillofac Surg.* 2010 Dec;14(4):247–52.
13. Oliveira BH, Campos V, Marcal S. Compound odontoma—diagnosis and treatment: three case reports. *Pediatr Dent.* 2001;23:151-157.